

# IS INTRA-TUMORAL BUDDING CORRELATED WITH LIVER METASTASIS IN PATIENTS WITH GRADE 2 COLORECTAL CANCER? A pilot study

URSULA THIEM<sup>1</sup>, RADU ROGOJANU<sup>1,4</sup>, ILDIKO MESTERI<sup>2</sup>, ISABELLA ELLINGER<sup>1</sup>, THERESIA THALHAMMER<sup>1</sup>, ANDREAS HEINDL<sup>3</sup>, ALEX SEEWALD<sup>3</sup>, GIOVANNA BISES<sup>1</sup>

<sup>1</sup>Department of Pathophysiology and Allergy Research, Center for Pathophysiology, Infectiology and Immunology, Medical University of Vienna, Austria; <sup>2</sup>Clinical Institute for Pathology, Medical University of Vienna, Austria; <sup>3</sup>Seewald Solutions, Vienna, Austria; <sup>4</sup>TissueGnostics GmbH, Vienna, Austria

## BACKGROUND

During cancer progression the normal epithelial structure is lost. Due to dedifferentiation epithelial cells undergo epithelial-mesenchymal transition, which allows cellular movement (1). Thereby, single cells are able to bud. They enter the circulation or the lymphatic system and form tumor foci at distant sites. This phenomenon is called tumor budding and is defined as presence of single epithelial cells or small epithelial cell clumps (up to five cells) in the stroma (2). Budding occurs particularly at the invasive front of tumor tissue. Recently, it was proposed that budding at the tumor center, intra-tumoral budding, is an independent prognostic factor in colorectal cancer (3).

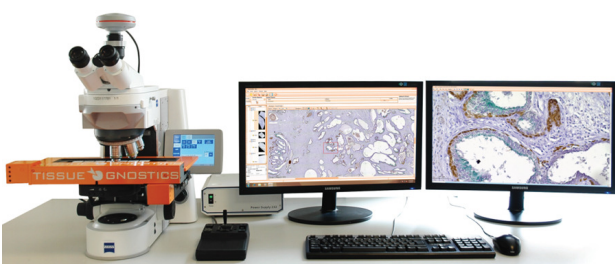## AIM

In this pilot study, we evaluated intra-tumoral budding in patients with colorectal cancer grade 2 and correlated it with the presence of liver metastasis.

## METHODS

We performed immunofluorescence staining studies on paraffin-embedded sections from 8 patients with colorectal cancer grade 2. Four of them had already developed liver metastasis. Epithelial cells were identified by an anti-keratin 8 antibody, microvessels by an anti-CD34 antibody, cells in epithelial-mesenchymal transition by an anti-β-catenin antibody and the respective fluorochrome-labeled secondary antibodies. Nuclei were stained with DAPI. Large areas of tumor tissue (150-300 mm<sup>2</sup>) were scanned using an automated microscopy system (TissueFAXS™, TissueGnostics GmbH) (Figure 1). For every section, depending on its size, we defined 2 to 10 tumor center sub-regions at a distance of 500-1000 μm from the border. These sub-regions were between 2,23 mm<sup>2</sup> and 40,22 mm<sup>2</sup> in size. In a virtual image of stained tissue, budding was assessed in the defined sub-region and related to its area size.

Figure 1. Automated microscopy system



Supported by the FFG Bridge-Project [818094].

## RESULTS

Figure 2. Intra-tumoral budding in patients with colorectal cancer grade 2

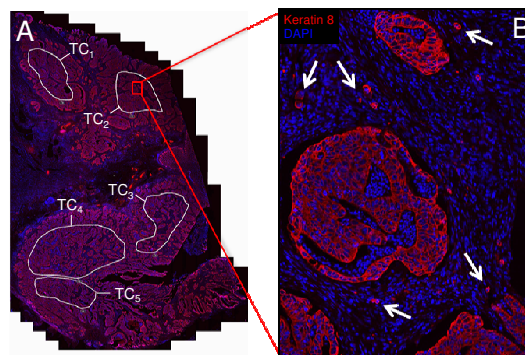


Figure 2. (A) After preparation of virtual slides of tumor tissue, tumor center sub-regions (TC<sub>1-5</sub>) were defined. (B) In these sub-regions, we manually assessed budding, i.e. up to five epithelial cells. Tumor buds are marked with arrows in a representative field of view (20x magnification, 711 x 523 μm). Keratin 8 as a marker for epithelial cells is labeled in red, nuclei are stained with DAPI (blue).

Figure 3. Epithelial cell buds, microvessels, and β-catenin

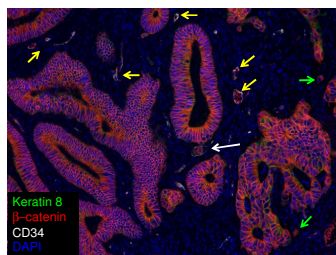


Figure 3. Immunofluorescence staining for CD34 (white), β-catenin (red), and Keratin 8 (green) in a tissue specimen from a colorectal cancer patient without liver metastasis. Microvessels are marked with yellow arrows, tumor buds with green arrows. The white arrow shows a microvessel containing a single epithelial cell in epithelial-mesenchymal transition. Epithelial-mesenchymal transition is indicated by the translocation of β-catenin from the membrane into the cytoplasm.

Figure 4. Comparison of intra-tumoral budding of colorectal cancer patients with and without liver metastasis

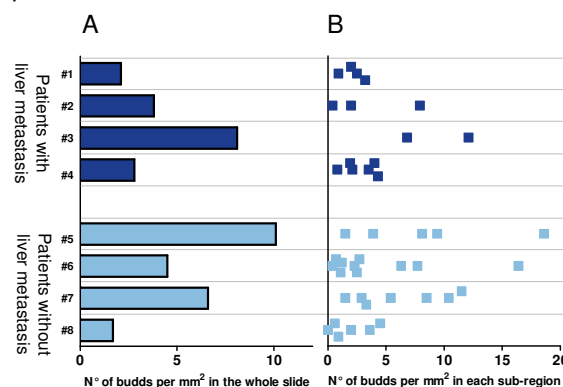


Figure 4. Intra-tumoral budding was manually assessed in tissue specimens of 4 colorectal cancer patients with liver metastasis (#1 - #4) and 4 without liver metastasis (#5 - #8). Results are presented as buds per mm<sup>2</sup>. (A) The total number of buds counted in each specimen was related to the overall tumor center area. (B) Each tumor center sub-region is represented by a square.

In our study group a high intra-individual variability was found, more pronounced in patients without liver metastasis.

## CONCLUSION AND FUTURE DIRECTIONS

Our data suggest no correlation between intra-tumoral budding and the presence of liver metastasis in patients with colorectal cancer grade 2. This might be due to the limited number of patients. Therefore, we propose assessing intra-tumoral budding in a larger cohort of patients. Furthermore, we aim to evaluate budding in relation to other factors such as distance to blood and/or lymphatic vessels.

## REFERENCES

- (1) Moreno-Bueno G. et al. Cancer Res 2006, 66, 9543-56.
- (2) Prall F. Histopathology. 2007, 50, 151-162
- (3) Lugli A. et al. Human Pathology. 2011, June 9 [Epub ahead of print]